

## REVIEW

# Physeal injuries in children's and youth sports: reasons for concern?

D Caine, J DiFiori, N Maffulli



*Br J Sports Med* 2006;40:749–760. doi: 10.1136/bjsm.2005.017822

A systematic review of the literature on the frequency and characteristics of sports related growth plate injuries affecting children and youth in organised sport was carried out. Both acute and chronic physeal injuries related to participation in sports have been reported to occur, although injury incidence data are somewhat limited. Of particular concern is the growing number of stress related physeal injuries, including those affecting the lower extremities. Although most physeal injuries appeared to resolve with treatment and rest, there is also evidence of growth disturbance and deformity. Possible injury risk factors and countermeasures are discussed, and suggestions for directing future research provided.

physis, epiphyseal, physeal, athletic injuries, sports, injury, and injuries. Each title was searched manually for any focus on growth plate injuries involving the long or tubular bones of young athletes. Titles focusing on sport related apophyseal injuries were excluded given the focus of the present review on injuries that may adversely affect growth. The reference lists of selected articles were searched using the same criteria.

Most reports retrieved were case reports or case series investigations where the characteristics of a series of people who were injured are detailed. These investigations allow a comprehensive account of the characteristics and relative frequency of sport related physeal injuries. However, they do not allow calculation of incidence rates or the identification of risk factors unless denominator data are available. The literature on the epidemiology of paediatric sports injuries was next searched in order to obtain, as far as possible, an insight into the prevalence and incidence of growth plate injuries in children's and youth sports.

## ANATOMY AND PHYSIOLOGY OF THE PHYSIS

The growing parts of the bone include the physis and the epiphysis. Two types of epiphyses are found in the extremities: traction and pressure. Traction epiphyses (or apophyses) are located at the site of attachment of major muscle tendons to bone and are subjected primarily to tensile forces. The apophysis of the tibial tubercle provides an example (fig 1). The apophyses contribute to bone shape but not to longitudinal growth.<sup>3</sup> As a result, acute or chronic injuries affecting traction growth plates are not generally associated with disruption of longitudinal bone growth. Overuse apophyseal conditions, such as Osgood-Schlatter disease, Sever's disease, and medial epicondylopathy in the throwing arm, are common in young athletes and may be the source of significant discomfort and time lost from training.

Pressure epiphyses are situated at the end of long bones and are subjected to compressive forces. The epiphyses of the distal femur and proximal tibia are examples of pressure epiphyses (fig 1). The growth plate or physis is located between the epiphysis and metaphysis and is the essential mechanism of endochondral ossification.<sup>4</sup> In contrast with traction growth plates, injury to pressure epiphyses and their associated growth plates may result in growth disturbance. Physeal injuries of the latter type sustained in organised sport are the focus of this article.

Participation in children's and youth sports is widespread in Western culture. Many of these youngsters initiate year round training and specialisation in their sports at a very early age. Preteens training at regional training centres or with high school and club teams in sports such as gymnastics may train 20 or more hours a week. In addition, many youngsters travel with select soccer or hockey teams to other towns and communities to compete on a regular basis. Increased involvement and difficulty of skills practiced at an early age and continued through the years of growth, with the level of intensity required to be competitive, raises concern about risk and severity of injury to young athletes.

In particular, the concern is that the tolerance limits of the physis may be exceeded by the mechanical stresses of sports such as football and hockey or by the repetitive physical loading required in sports such as baseball, gymnastics, and distance running.<sup>1–2</sup> Disturbance of physeal growth as a result of injury can result in length discrepancy, angular deformity, or altered joint mechanics and may cause significant long term disability. This article describes the present status of knowledge on the frequency and characteristics of physeal injuries affecting children and youth involved in organised sport. In doing so, possible risk factors are elucidated that may assist in developing specific recommendations for injury prevention and for directing future research.

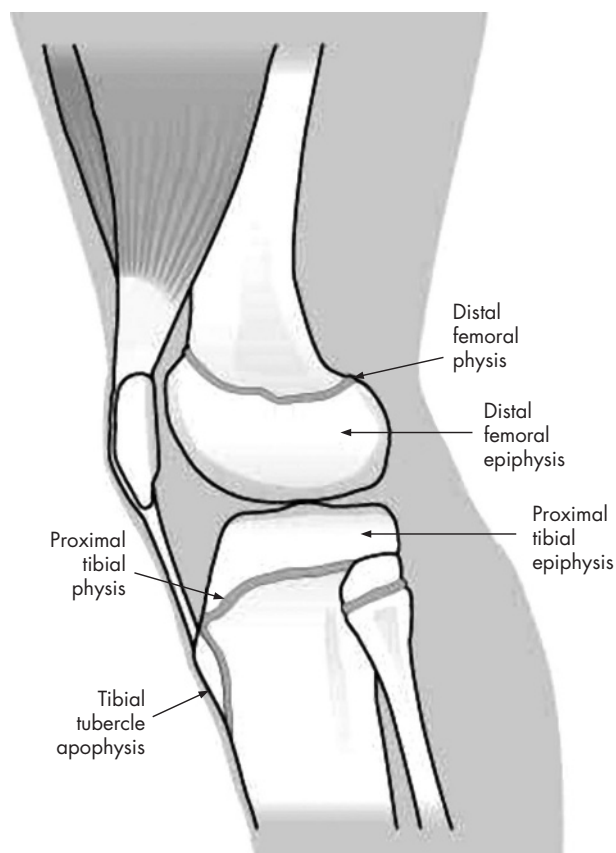
## METHODS

A literature review was undertaken using Medline and SPORTDiscus. The search was restricted to English language articles. Medical subject headings and text words included: growth plate,

See end of article for authors' affiliations

Correspondence to:  
Dr Caine, Department of  
Physical Education, Health  
and Recreation, Western  
Washington University,  
Bellingham, WA 98225-  
9067, USA; Dennis.  
Caine@wwu.edu

Accepted 23 April 2006  
Published Online First  
6 July 2006



**Figure 1** An illustration of the location of the physes and epiphyses of the distal femur and proximal tibia, and the tibial tubercle apophysis. Illustration by Kevin Short. From Caine.<sup>1</sup> Reprinted with permission from S Karger AG, Basel.

Briefly, as explained by Ogden,<sup>4</sup> in the zone of “growth”, germinal cells are attached to the epiphysis and obtain their vascular supply from the epiphyseal artery. Longitudinal growth is accomplished by the proliferation of these cells. The zone of growth is the area of greatest concern with any fracture involving the growth plate, as damage to cells in this zone may have long term consequences for normal growth patterns.

The next functional area is the zone of cartilage “maturation”. Increased extracellular matrix is formed in this zone, primarily between columns. The extracellular matrix exhibits cell mediated biomechanical changes, then calcifies. The cells align in vertical columns as they hypertrophy and are eventually replaced by osteoblasts. Fractures most commonly occur at the junction of calcified and uncalcified hypertrophic cells because it is structurally the weakest portion of the growth plate.<sup>4</sup>

In the zone of cartilage “transformation”, the cartilaginous matrix is penetrated by metaphyseal vessels, which break down the transverse cartilaginous septa, allowing invasion of mature cell columns. The cartilage and the bone are remodelled, removed, and replaced by a more mature, secondary spongiosa, eventually containing no remnants of the cartilaginous precursor.<sup>4</sup>

### SUSCEPTIBILITY TO INJURY

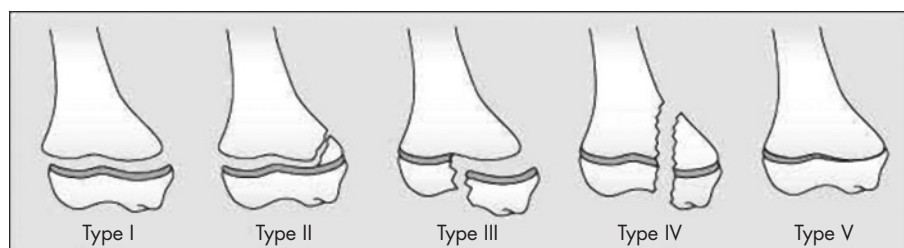
Physal injuries may produce irreversible damage to the growing cells, resulting in growth disturbance. Growth plate cartilage is less resistant to stress than adult articular cartilage.<sup>5-6</sup> It is also less resistant than adjacent bone to shear and tension forces. Therefore, when disruptive forces are applied to an extremity, failure may occur through the physis. In addition, the physis may be 2–5 times weaker than the surrounding fibrous tissue.<sup>7</sup> For these reasons, injury mechanisms that in an adult may result in a complete tear of a ligament or in a joint dislocation may produce a separation of the growth plate in a child.

The susceptibility of the growth plate to injury appears to be especially pronounced during periods of rapid growth.<sup>4, 5, 8-17</sup> Research on the development of physal cartilage in animals shows a decrease in physal strength during pubescence.<sup>8</sup> The data on humans are consistent with these findings.<sup>9-11</sup> An increase in the rate of growth is accompanied by structural changes that result in a thicker and more fragile plate.<sup>9, 12</sup> In addition, bone mineralisation may lag behind bone linear growth during the pubescent growth spurt, rendering the bone temporarily more porous and more subject to injury.<sup>13</sup> Studies of the incidence of physal injuries in humans indicate an increased occurrence of fractures during pubescence,<sup>12-16</sup> with the peak fracture rate probably occurring at the time of peak height velocity.<sup>13</sup>

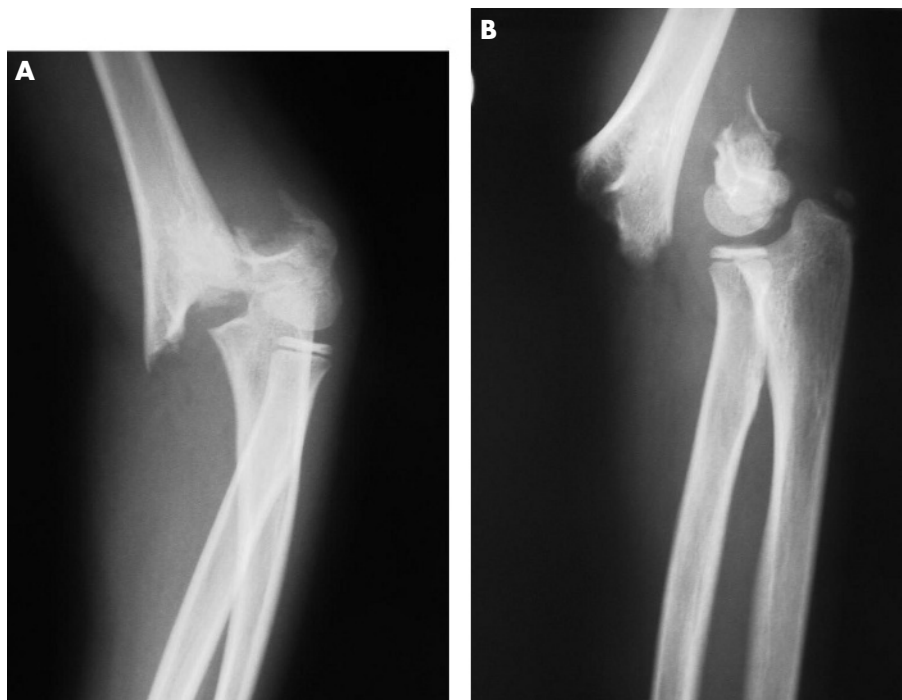It has been proposed that the growth spurt may also increase susceptibility to growth plate injury by causing an increase in muscle-tendon tightness about the joints and an accompanying loss of flexibility.<sup>18</sup> However, this concept is controversial.<sup>19</sup> Longitudinal growth occurs initially in the long bones of the extremities, and the muscle-tendon units elongate in response to this change. This may create a temporary disparity between muscle-tendon and bone lengths. If an excessive muscular stress is applied, a muscle-tendon imbalance is produced that may predispose to injury.<sup>20</sup> Because the joint, and in particular the growth cartilage, is the weak link in this assembly, it is believed that the risk of injury may be increased at this site during the growth spurt.<sup>18</sup> However, Feldman *et al*<sup>19</sup> have questioned whether a reduction in flexibility occurs during the adolescent growth spurt.

### ACUTE PHYSEAL INJURY

Although more elaborate classification systems for describing acute physal injuries are available,<sup>4</sup> the system most widely



**Figure 2** An illustration of the types of growth plate injury as classified by Salter and Harris.<sup>21</sup> Illustration by Kevin Short. From Caine.<sup>1</sup> Reprinted with permission from S Karger AG, Basel.



**Figure 3** A radiographic illustration of a Salter-Harris type II supracondylar fracture of the humerus in a 9 year old male gymnast who fell badly after a vault.

used was developed by Salter and Harris.<sup>21</sup> Figure 2 shows the different types of injury in this classification. Type I injuries show a complete separation of the epiphysis from the metaphysis without any bone fracture. The germinal cells of the growth plate remain with the epiphysis, and the calcified layer remains with the metaphysis. In type II, the most common physal injuries, the line of separation extends along the growth plate, then out through a portion of the metaphysis, producing a triangular shaped metaphyseal fragment sometimes referred to as the Thurston Holland sign. Type III, which is intra-articular, extends from the joint surface to the weak zone of the growth plate and then extends along the plate to its periphery. In type IV, often involving the distal humerus, a fracture extends from the joint surface through the epiphysis, across the full thickness of the growth plate and through a portion of the metaphysis, thereby producing a complete split. In type V, a relatively uncommon injury, there is a compression of the growth plate, thereby extinguishing further growth.

Prognosis for types I and II fractures is good if the germinal cells remain with the epiphysis, and circulation is unchanged. However, these injury types are not as innocuous as originally believed, and can be associated with risk of growth impairment.<sup>4 16 22–28</sup> Figure 3 provides a radiographic depiction of a Salter-Harris type II injury in a young male gymnast. Type III injuries have a good prognosis if the blood supply in the separated portion of the epiphysis is still intact and if the fracture is not displaced. Surgery is sometimes necessary to restore the joint surface to normal. In type IV injuries, surgery is needed to restore the joint surface to normal and to perfectly align the growth plate. Type IV injuries have a poor prognosis unless the growth plate is completely and accurately realigned.

Studies of more than 200 specimens of simultaneously occurring physal fractures in children (usually from traumatic amputation) and skeletally immature zoo animals indicate that the typical physal fracture occurs within the hypertrophic zone.<sup>4</sup> The most common level was the junction of calcified and

uncalcified hypertrophic cells. However, variation in fracture propagation may occur that relates to extent of physical maturity, the amount of force applied, rates of loading, and particularly the application of forces.<sup>4 8 29 30</sup> In addition to the variable undulation of the fracture plane in physal injuries, an important finding is microdisruption in the germinal zone that is separate from the main cleavage plane.<sup>4</sup>

Approximately 15% of all fractures in children involve the physis.<sup>4 31</sup> Acute growth plate injuries such as those incurred by falling off bicycles, skateboards, playground equipment, out of trees, and so forth, are common to many childhood misadventures. In one large population based study of growth plate injuries, the largest single group of physal fractures occurred as a result of a fall, usually while running or playing around furniture or playground equipment.<sup>14</sup> Competitive sports—for example, hockey, football, baseball—accounted for 33.5% and recreational activities—biking, skateboarding, skiing—for 21.7% of physal injuries in this study. In several studies, organised sports accounted for more physal injuries than recreational activities.<sup>11 14 16 25 32 33</sup> American football is the sport most often connected with acute physal fractures; however, most other sports are also represented.<sup>14 16 25 27</sup> Motor vehicle accidents, including motorcycles and all-terrain vehicles, also account for a significant number of especially severe physal injuries.

Reports on acute physal conditions affecting young athletes are abundant and arise primarily from case reports and case series data involving mostly male athletes (table 1).<sup>34–66</sup> These injuries were incurred in a variety of sports, although football is the sport most often reported. Injury outcome was generally good with growth disturbance reported in only eight of 50 cases; however, the length of follow up was brief or not reported in some cases. Most of the athletes were advanced in age (13–17 years), limiting the amount of growth disturbance possible.

Table 2 summarises case series reporting growth plate fractures.<sup>11 14 16 22 24 25 27 32 33 67–74</sup> With the exception of two studies that reported on only sport related physal injuries,

**Table 1** Case reports including data on sports related physal fractures

Study	No of cases	Age (years)	Injury location	Salter-Harris injury type	Sport	Outcome
Rogers <sup>34</sup>	1 M		Distal femur	I	Football	
Rovere <sup>35</sup>	1 M	12	Distal femur	I	Football	Follow up not reported; "satisfactory"
Ryan <sup>36</sup>	5 M	14–16	Distal radius	II	Weight lifting	
Simpson <sup>37</sup>	3 M	15–17	Distal femur	I	Football	Follow up 5–27 months; "significant leg length discrepancy in one case"
Gumbs <sup>38</sup>	2 M	12, 14	Distal radius and ulna	II	Weight lifting	Follow up time not reported; "healing was uneventful"
Collins <sup>39</sup>	1 M	10	Distal tibia	II	Soccer	Follow up 4 months; no growth disturbance evident
Lemire <sup>40</sup>	1 M	15	Medial clavicle	I	Hockey	Follow up 1 year; "return to normal activity without problems"
Hernandez <sup>41</sup>	1 M	11	Distal radius	II	Basketball	Follow up 8 years; premature closure
Jenkins <sup>42</sup>	1 M	13	Bilateral distal radius; distal tibia	II	Football	Follow up not reported
Abrams <sup>43</sup>	1 F	15	Proximal fibula	III	Gymnastics	Follow up 7 weeks; "progressive healing"
Spinella <sup>44</sup>	1 F	15	Distal tibia	III	Figure skating	Follow up 3 years; no growth disturbance
Weiss <sup>45</sup>	1 M	14	Distal tibia	III	Football	Follow up 1 year; "uneventful"
Thomas <sup>46</sup>	1 M	16	Distal radius	I	Weight lifting	Follow up not reported
	1 M	13	Distal tibia	IV	Football	Follow up 6 months; "some early closure of the physis was evident on comparison studies"
Keret <sup>47</sup>	1 M	13	Proximal tibia	V	Football	Follow up 2 years; premature closure; also associated premature partial closure of the distal femoral physis
Bak <sup>48</sup>	1 M	14	Proximal tibia	II	Gymnastics	Follow up 9 months; premature closure
Meyers <sup>49</sup>	1 M	15	Distal femur	II	Football	Follow up 1 year; normal anatomical alignment and equal leg lengths
Hartley <sup>50</sup>	1 M	15	Proximal tibia	IV	Soccer	Follow up 4 months
Toto <sup>51</sup>	1 M	17	Distal fibula	I	Baseball	Follow up not reported
Banks <sup>52</sup>	2 M	16, 17	Proximal tibia	II	basketball	Follow up 3 months – 2 years; no growth disturbance in the boy followed for 2 years
Decoster <sup>53</sup>	1 M	14	Distal femur	III	Football	Follow up 1 year; "significant growth discrepancy unlikely because he was so near skeletal maturity"
Valverde <sup>54</sup>	1 M	13	Distal radius	V	Football	Follow up 21 months; premature closure
Goldberg <sup>55</sup>	1 M	11	Distal femur	III	Football	Follow up 2 years; non-union
Beck <sup>56</sup>	1 M	18	Proximal tibia			Premature closure of the lateral part of the proximal tibia subsequent to a sports injury at age 6
Brone & Wroble <sup>57</sup>	3 M	14–16	Distal femur	III	Football	Follow up 2–3 years; no limb length discrepancy or limb deformity
Veenema <sup>58</sup>	2 M	15	Distal femur	III	Football	Follow up 4 months; "no evidence of limb length discrepancy or angular deformity"
Mudgal <sup>59</sup>	1 M	16	Proximal tibia	I	Basketball	Follow up 6 months; "no evidence of limb length discrepancy or angular deformity"
Shinro <sup>60</sup>	1 M	13	Proximal tibia	II (right) I (left)	Basketball	Follow up 5.5 years; "no deformities or differences in leg length were observed"
Maffulli <sup>61</sup>	2 M	11, 14	Proximal phalanx of the hallux	III	Judo, soccer	Follow up 3–4 years; "no evidence of growth disturbance or osteoarthritis"
Ozer <sup>62</sup>	1 M	17	Proximal tibia	III	Basketball	Follow up 4 months
Whan <sup>63</sup>	1 M	16	Proximal tibia	I	Gymnastics	
Egun <sup>64</sup>	1 M	16	Proximal tibial		Basketball	Follow up 27 months; "no angular deformity"
Goga & Gongal <sup>65</sup>	3 M		Distal femur	III	Soccer	
	1 M		Proximal tibia	II	Soccer	
	1 M		Distal tibia	II	Soccer	
Samsoni <sup>66</sup>	1 F	14	Distal femur	II	Cricket	Follow up 6 months; "early indication of growth arrest on the medial side"

The sex of the patients is indicated: M, male; F, female.

**Table 2** Case series including data on sports related physal fractures

Study	Total no of growth plate fractures	Location	No of growth plate fractures associated with organised sports	No of sports related growth plate fractures associated with growth disturbance
Larson <sup>67</sup>	84	All	59 (70)	
Stephens <sup>68</sup>	20	Distal femur	7 (35)	5 (71)
Criswell <sup>69</sup>		Distal femur	15 (100)	3 (20)
McManama <sup>70</sup>	135	All	35 (26)	13 (37)
Lombardo <sup>77</sup>	34	Distal femur	4 (12)	3 (75)
Goldberg <sup>25</sup>	53	Distal tibia	19 (33)	5 (26)
Burkhard <sup>24</sup>	28	Distal tibia	8 (28)	2 (25)
Benton <sup>16</sup>	203	All	79 (39)	4 (5)
Speer <sup>11</sup>	134	All	29 (22)	
Cass <sup>71</sup>	18	Distal tibia	1 (6)	0 (0)
Krueger-Franke <sup>33</sup>		Lower extremity	85 (100)	9 (11)
Lalonde <sup>72</sup>	12	Distal tibia	3 (25)	1 (33)
Peterson <sup>14</sup>	951	All	327 (34)	
Fischer <sup>32</sup>	378	Hand	129 (34)	
Rhemrev <sup>73</sup>	6	Proximal tibia	1 (17)	0 (0)
Barmada <sup>22</sup>	92	Distal tibia	22 (24)	
Nenopoulos <sup>74</sup>	9	Distal tibia	3 (33)	0 (0)

Values in parentheses are percentages.

the studies reviewed reveal a wide range in the proportion of fractures associated with organised sports (5.6–72.8%), and a wide range that were associated with growth disturbance (0–75%).

Most cohort studies reporting on the nature and incidence of paediatric sports injuries describe the frequency of fractures without specifying the frequency or severity of physal fractures.<sup>75–76</sup> There is also rarely any follow up to indicate the outcome of physal injuries. Table 3 provides a summary of cohort studies that do provide information on the frequency of physal fractures in several sports.<sup>77–89</sup> Perusal of these reports reveals that 1–30% of paediatric sports injuries are acute physal injuries. Of concern in these reports is the finding that sprains were common injuries and that not all injuries were seen by a doctor. As discussed above, an injury that would cause a sprain in an adult can be a potentially serious growth plate injury in a child.

**CHRONIC PHYSEAL INJURY**

An accumulating number of clinical reports indicate that sport training, if of sufficient duration and intensity, may precipitate pathological changes of the growth plate and, in extreme cases, produce growth disturbance. This injury appears to occur through repetitive loading, which alters metaphyseal perfusion and in so doing interferes with the mineralisation of the hypertrophied chondrocytes, which

typically occurs in the zone of provisional calcification.<sup>4</sup> The hypertrophic zone continues to widen because of constant growth in the germinal and proliferative zones,<sup>4</sup> as shown experimentally by Jaramillo *et al.*<sup>90</sup> MRI findings of distal radial physal injury reported in Chinese acrobats and young competitive gymnasts<sup>91–92</sup> resemble the experimentally induced injuries described by Jaramillo *et al.*<sup>90</sup>

Briefly, as explained by Ogden,<sup>4</sup> the widening of the growth plate within the hypertrophic zone is usually temporary, as the resting and dividing cellular layers of the growth plate, and the attendant epiphyseal and metaphyseal blood supplies, are essentially undisturbed. However, in some situations, this ischaemic condition may lead to osseous necrosis and deformity within the developing ossification centre and to growth irregularities in the physis. These changes may be localised and cause asymmetric growth, or they may involve the entire physis and result in an overall slowdown of the rate of growth or even complete cessation of growth. In either case, premature closure of some or all of the physis may occur.<sup>4</sup>

Baseball pitchers were perhaps the first young athletes recognised to present with stress related injury of the physis.<sup>93</sup> Table 4 shows studies reporting stress changes or stress fracture of the proximal humeral physis in young baseball pitchers.<sup>93–104</sup> Often associated with persistent pain in the throwing arm, stress changes of the proximal humeral

**Table 3** Cohort studies including data on sports related physal injuries

Study	Design	Duration	Sample	No of participants	No of injuries	% physal injuries
Roser <sup>77</sup>	Prospective	1 season	Football	2048	48	3
Chambers <sup>78*</sup>	Prospective	1 year	Six sports	2803	20	30
Zaricznyj <sup>79</sup>	Prospective	1 year	All sports	25 512	1495	1
Goldberg <sup>80</sup>	Prospective	1 season	Football	436	67	3
Tursz <sup>81*</sup>	Prospective	1 year	All sports	62 800	789	10
Goldberg <sup>82</sup>	Prospective	1 season	Football	5128	257	5
Caine <sup>83†</sup>	Prospective	1 year	Gymnasts	50	147	6.8
Risser <sup>84</sup>	Prospective	1 year	Weight training	217	27	7.4
Andreassen <sup>85</sup>	Prospective	1 tournament	Soccer	12 907	132	6
Linder <sup>86</sup>	Prospective	2 seasons	Football	340	55	9.1
Koli <sup>87†</sup>	Retrospective	1 year	Gymnastics	162	321	11.5
Koli <sup>88†</sup>	Prospective	18 months	Gymnastics	64	349	12.3
Stuart <sup>89</sup>	Prospective	1 season	Football	915	55	7

\*Hospital based study.  
†Includes acute and overuse physal injuries.

**Table 4** Pathological changes involving the proximal humeral physis in baseball players

Study	No of subjects	Age range	Radiographic changes involving the proximal humeral physis
Dotter <sup>93</sup>	1	12	Physal widening, adjacent osteoporosis
Adams <sup>94</sup>	5	13–15	Accelerated growth and physal widening, demineralisation, and apparent fragmentation without aseptic necrosis
Torg <sup>95</sup>	1	12	Physal widening
Cahill <sup>96</sup>	1	–	Physal widening with metaphyseal bone separation
Tullos <sup>97</sup>	1	12	Osteochondritis with abundant callus formation
Lipscomb <sup>98</sup>	3	–	–
Hansen <sup>99</sup>	1	14	Physal widening
Barnett <sup>100</sup>	1	–	–
Albert <sup>101</sup>	1	–	Physal widening
Carson <sup>102</sup>	23	11–16	Radiographic widening of the proximal humeral growth plate
Ricci <sup>103</sup>	1	–	Physal widening
Flemming <sup>104</sup>	1	12	Physal widening

growth plate, or “Little league shoulder”, represent sequelae of repetitive traction and rotational forces across the epiphysis and growth plate.<sup>99</sup> In most cases, subjects improved with rest and were able to return to baseball, albeit in some cases to a position other than as pitcher. In one instance there was premature closure of the proximal humeral physis.<sup>102</sup>

Similar cases of stress related proximal humeral physal widening (Salter-Harris type 1 fractures) have been reported in other young athletes involved in overhead sports including: cricket,<sup>105</sup> gymnastics,<sup>106</sup> badminton,<sup>107</sup> and swimming and volleyball.<sup>108</sup> Johnson and Houchin<sup>108</sup> suggest that this condition may be more appropriately termed “adolescent athlete’s shoulder.” Chronic physal injuries affecting the distal humerus and proximal radius of young baseball players are also documented.<sup>109–110</sup> Stress related physal fractures of

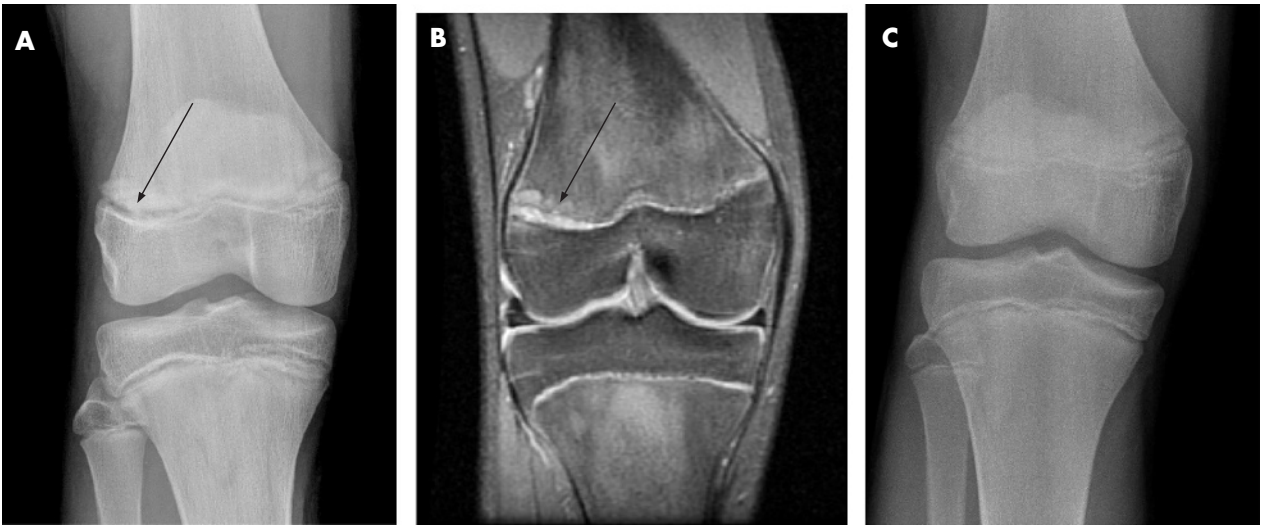
the middle phalanx of the finger have also recently been reported in young sport climbers.<sup>111</sup>

Table 5 summarises case data on stress related lower extremity physal injuries involving paediatric athlete participants representing a variety of sports and activities.<sup>112–121</sup> In these cases, diagnosis of physal stress fracture was based on widening of the physis and irregularity of the metaphyseal line or fragmentation or separation of the metaphysis. Symptoms arose primarily from running related activities, including long distance running. Most subjects improved with rest and were able to return to their sport. However, in one case<sup>119</sup> there was a premature closure of the right proximal tibial growth plate, and in another,<sup>121</sup> bilateral varus deformity of the knees. In the latter case, the subject was non-compliant and continued vigorous tennis training despite physician prescription for rest.

**Table 5** Pathological changes involving lower extremity physes in young athletes

Study	No of subjects	Age (years)	Activity	Radiographic changes
Cahill <sup>112</sup>	1 M	15.5	Long distance running	Widening of proximal tibial growth plate with metaphyseal bone separation
Percy <sup>113</sup>	1 M	16	Long distance running	Widening of first metatarsal growth plate with metaphyseal separation
Godshall <sup>114</sup>	2 M	14.5	Running during basketball or football training	Widening and a loss of normal architecture of the distal femoral growth plate
Weber <sup>115</sup>	1 M	15	Tennis	Widening of the distal femoral growth plate with metaphyseal bone separation
Liebling <sup>116</sup>	1 M	13	Baseball (catcher)	Physal widening and metaphyseal irregularity in parts of the proximal tibia and distal parts of the femurs
Wall <sup>117</sup>	1 F	11	Gymnastics	Knee MRI revealed severe widening of the proximal tibial growth plate
Wall <sup>118</sup>	18 M/F	11.3	Soccer, baseball, football	Mild growth plate widening in two cases, although all subjects had chronic ankle pain and tenderness to palpation localised to the distal tibial/fibular growth plates
Sato <sup>119</sup>	1 F	13	Basketball	Premature closure of the lateral side of the right proximal tibial growth plate
Nanni <sup>120</sup>	1 M	15	Rugby ball kicking	Wide separation of the proximal tibial epiphysis, asymmetrically affecting the medial side more than the lateral side
Laor <sup>121</sup>	6 (3M; 3F)	12.3	Basketball, football place kicking, gymnastics, tennis, soccer, football	MRI findings showing widening of the distal femoral and/or proximal tibial growth plates

The sex of the patients is indicated: M, male; F, female.  
MRI, Magnetic resonance imaging.



**Figure 4** Fifteen year old male football place kicker. (A) Frontal radiograph and (B) magnetic resonance image of right knee showing physal widening of lateral aspect of distal femoral physis (arrow). (C) Frontal radiograph obtained three months after immobilisation showing near complete resolution of physal widening. From Laor *et al.*<sup>121</sup> Reprinted with permission from the *American Journal of Roentgenology*.

Notably, in one case, a stress reaction of the proximal tibial growth plate developed in response to extreme repetitive rotational and pressures forces on the epiphysis associated with the practice of rugby place kicking.<sup>120</sup> The mechanism of injury is believed to be similar to that seen from overuse in the proximal humeral epiphysis of throwing athletes.<sup>120</sup> In a second, similar case,<sup>121</sup> stress injury of the distal femoral physis developed in a football place kicker (fig 4). Clinical resolution of symptoms in this case occurred in 23 days.

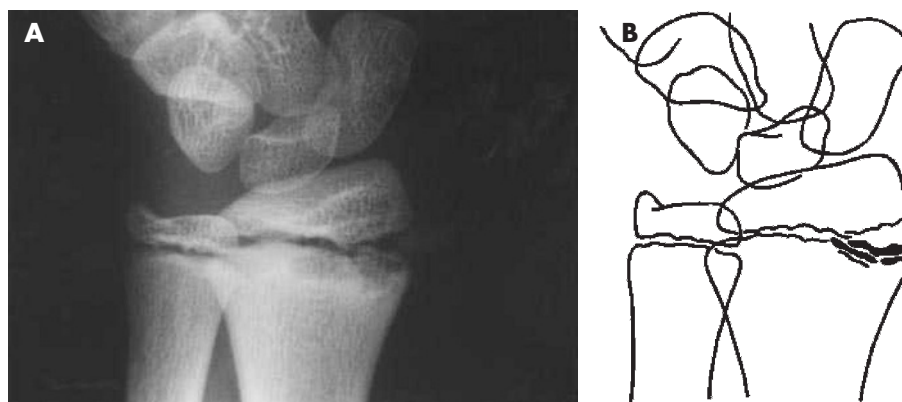
The most commonly reported physal stress injuries have been those affecting the distal radial physes of young gymnasts.<sup>91 122–137</sup> Most reports describe distal radius stress

reaction with a radiographically widened and irregular physis, especially on the metaphyseal side. However, Read<sup>122</sup> reported stress fractures of the epiphysis and metaphysis in the distal radii of young female gymnasts. Table 6 summarises case data on stress related physal injuries involving the distal radius of gymnasts.

Figure 5 shows an illustration of the stress injured distal radial physis of a gymnast. In the studies reviewed (table 6), almost all patients with stress related injury affecting the distal radius recovered with rest, and did not experience premature physal closure or abnormal growth. However, there are four subsequent reports of distal radius physal

Table 6 Case reports and case series of physal injuries involving the distal radius of gymnasts				
Study	No of subjects	Age (years)	Competitive level	Results
Read <sup>122</sup>	3 F	13.7		Stress fractures involving the epiphysis and metaphysis of the distal radius
Roy <sup>123</sup>	10 F 1 M	12.2 12	II, I, elite	Stress changes, possibly stress fractures of the distal radial growth plate
Fliegel <sup>124</sup>	1 F 1 M	14 14		Stress induced widening of the distal radial growth plate
Vender <sup>125</sup>	1	17		Premature bilateral closure of the ulnar side of the distal radial growth plate leading to a Madelung-like deformity
Carter <sup>126</sup>	4 F	14	National, club	Salter type I stress fractures of the distal radial growth plate due to chronic repetitive force
Yong-Hing <sup>127</sup>	17 M	13.5	National	Stress related widening of the growth plates of the distal radius and ulna
Albanese <sup>128</sup>	1 M 3 F	13 13.3		Chronic overuse leading to premature growth plate closure, resulting in shortening of radius and alterations in the distal radioulnar articulation
Ruggles <sup>129</sup>	1 F	12	Elite	Bilateral widening of the distal radial growth plate
Li <sup>130</sup>	1 F	13		Widening and irregularities of the distal radial growth plate and flaring of the distal radial metaphysis with spurring along its palmar aspect
Frizzell <sup>131</sup>	1 M	14		Stress changes of the distal radial physis
Carek <sup>132</sup>	1 F	14		Stress fracture (epiphysiolysis) of the distal radial growth plate
Nattiv <sup>133</sup>	1 F	—		Repetitive injury to the distal radial physis leading to hindered radial growth
Liebling <sup>116</sup>	1 M	13	Club level	MRI findings showing widening of the distal radial growth plate and irregularity of the bordering metaphysis bilaterally
DiFiori <sup>91</sup>	1 F	10.5	Club level	Bilateral stress injury to the distal radial growth plates
Howe <sup>134</sup>	1 F	14	Club level	Premature closure of the right distal radial epiphysis
Bak <sup>135</sup>	1 F	14		Radiovolar opening of the distal radial physis and premature closure of the ulnar part of the distal radial physis
Brooks <sup>136</sup>	1 F	21		Traumatic physal arrest resulting in Madelung deformity

The sex of the patients is indicated: M, male; F, female.  
MRI, Magnetic resonance imaging.



**Figure 5** Radiograph (A) and line drawing (B) of the wrist in a symptomatic young female gymnast with findings of widening of the distal radial physis, breaking of the epiphysis, and cystic changes and irregularity of the metaphyseal margin. From Roy *et al.*<sup>123</sup> Reprinted with permission from The American Orthopedic Society for Sports Medicine.

arrest in skeletally immature female gymnasts.<sup>128 133–137</sup> Evidence of premature growth arrest in these reports was provided by repeated roentgenographic evaluations, which revealed discrepancies in radiographic status of the growth plates in the involved and uninvolved bones and extremities. Figure 6 shows an illustration of partial closure of the right distal radial physis in a 14 year old female gymnast.<sup>134 137</sup>

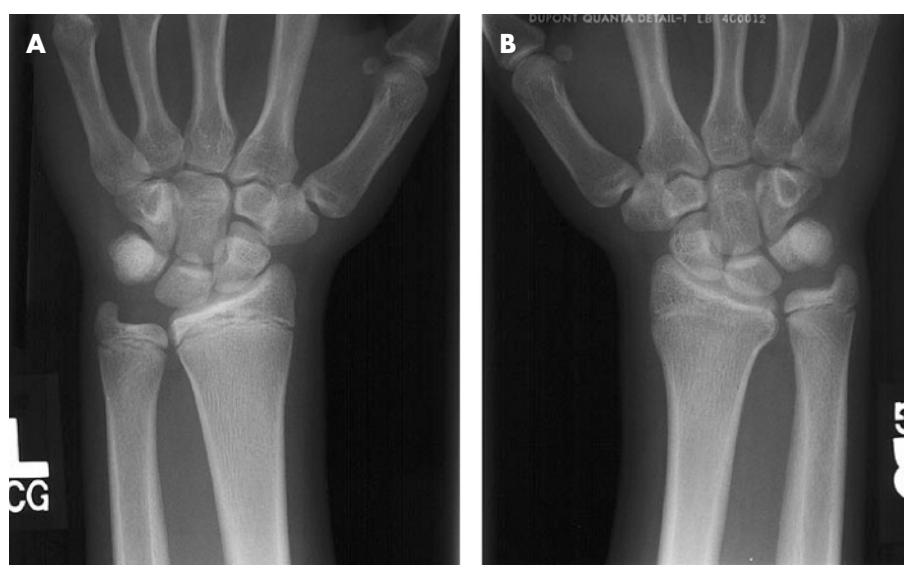There are also analogous reports of stress related premature physeal closure in other young people. Carson and Gasser<sup>102</sup> reported on an 11 year old pitcher with premature closure of the proximal humeral physis (table 4). Attkiss and colleagues<sup>138</sup> described an adolescent pianist with premature closure of the physis of the distal phalanx in the thumb, presumably caused by accumulated repetitive trauma incurred during years of piano playing. These reports are consistent with results from animal studies where prolonged intense physical loading inhibits or stops bone growth.<sup>139–144</sup>

In one case, radiographs of a young gymnast actually showed radioulnar opening of the distal radial physis and premature closure of the ulnar side of the distal radial physis.<sup>135</sup> A similar finding involving the lateral side of the right proximal tibial growth plate in a young basketball

player was described by Sato *et al.*<sup>119</sup> These data are consistent with results from animal studies that show that an increased compression on one side of an epiphysis may prevent growth on that side, whereas normal growth occurs on the other side.<sup>145</sup>

Prevalence data for stress related physeal injuries are currently provided only for male and female gymnasts (table 7). Eight cross sectional studies report radiographic abnormalities consistent with distal radius physeal stress reaction in 10–85% of subjects.<sup>17 123 146–151</sup> One cross sectional study<sup>92</sup> reported partial closure of the left distal radial growth plate in three gymnasts (two girls and one boy).

Lishen and Jianhua<sup>152</sup> reported on the nature and frequency of distal radius injury among 28 top level Chinese gymnasts who were followed and monitored radiographically over nine years. During this follow up, six of 18 girls and eight of 10 boys developed progressive wrist pathology. Initially, gymnasts developed chronic wrist pain associated with upper extremity weight bearing, with no radiographic abnormalities present. Next, x ray examination revealed stress changes involving the distal radial growth plate, with accompanying decreased range of motion at the



**Figure 6** Fourteen year old female gymnast with chronic right wrist pain. The image on the right is of the symptomatic right wrist and shows partial closure of the right distal radial physis. The ulnar physis remains open. The image on the left is of the asymptomatic left wrist. Both physes of the left wrist remain open. From Caine *et al.*<sup>137</sup> Reproduced with permission from Elsevier.

Table 7 Cross sectional studies of physal injuries affecting gymnasts

Study	No of subjects	Age (years)	Level	Diagnosis/condition
Auberge <sup>146</sup>	57 F	14–17	Junior national	Chronic osteoarticular lesions involving the distal radial growth plate (85%)
	41 M	17–33	Junior national	Chronic osteoarticular lesions involving the distal radial growth plate (80%)
Szot <sup>147</sup>	41 M	15–31	National	Distal radial epiphyseal irregularities (58.5%)
Roy <sup>123</sup>	26 F	9–14	Class II	Minimal widening and irregularity of the distal radial growth plate (30.8%)
Caine <sup>148</sup>	39 F	12.6	Class III, II, I	Minimal widening and irregularities of the distal radial physis (10%)
	21 M	12.6	Class IV, III, II, I	Definite changes of subchondral sclerosis, physal widening, marginal new bone formation, and distortion of the distal end of the radius (4.8%)
DeSmet <sup>149</sup>	156 F (not fused)	15.9	National	Enlargement of the distal radial growth plate with irregular borders in 10% of the cases; at baseline, 23 of 50 gymnasts had wrist pain
Chang <sup>150</sup>	176 (77 F; 99 M)	11–16	Chinese opera students	Unfused group: 10 girls (14.3%) and 32 boys (32.3%) showed stress related changes of the distal radial growth plate; 23 cases showed early partial closure of the distal radial growth plate
DiFiori <sup>151</sup>	44 (27 F; 17 M)	11.6	Non-elite	11 gymnasts (25%; M,F) showed radiographic evidence of stress injury to the distal radial physis
DiFiori <sup>17</sup>	59 (28 F; 31 M)	9.3	Club level	Wrist pain was reported by 56% (33 of 59) of the gymnasts, with 45% 15 (of 33) describing pain of at least 6 months; 51% of the gymnasts (30 of 59) had finding of stress injury to the distal radial physis of at least grade 2

The sex of the patients is indicated: M, male; F, female.

wrist. Finally, radiographs revealed hindered radial growth and a relatively lengthened ulna.

The case, cross sectional, and cohort data reviewed indicate the existence of stress related injury and, occasionally, stress related physal arrest. Along with results from animal studies, these findings suggest repetitive physical loading in excess of tolerance limits as a principle aetiological factor. Unfortunately, other potential aetiological factors such as nutrition, technique, and equipment have not been well studied.

REASONS FOR CONCERN

This review of the literature raises several important concerns related to growth plate injury among the paediatric athlete population.

- Acute growth plate injuries do occur in sport and may account for as much as 30% of injuries, as reported in one study.<sup>78</sup> However, the proportion of physal injuries is probably much less, ranging from 1% to 12% of injuries depending on the sport.<sup>77 79–89</sup> (table 3).
- Although 71–75% of sport related growth plate fractures were associated with growth disturbance in two studies,<sup>27 68</sup> the proportion of those with poor prognosis is probably much less, ranging from 0% to 37%.<sup>16 24 25 33 69 70–74</sup> (table 2).
- Type 1 and particularly type 2 Salter-Harris acute growth plate injuries are not as innocuous as originally described and may occasionally be associated with localised growth plate closure and osseous bridging.<sup>4 16 22–28</sup>
- There are accumulating reports of stress related physal injuries affecting young athletes in a variety of sports, including baseball, long distance running, basketball, football, soccer, gymnastics, rugby, tennis, and cricket. Although most of these stress related conditions resolved without growth complication during short term follow up, there are nonetheless several reports of stress related premature partial or complete physal closure.<sup>102 119 134–136 150</sup>
- There are two reports of varus changes subsequent to sports related stress injury to the distal femoral and/or proximal tibial physes (rugby and tennis players).<sup>120 121</sup>
- There is a paucity of epidemiological data on the distribution and determinants of growth plate injury in organised sports.

Finally, it is of great concern that many coaches of children and youth sports, although enthusiastic and well meaning volunteers, are otherwise largely uninformed about the

growth and development characteristics of children and youth and the appropriate care and prevention of athletic and particularly growth plate injuries.

INJURY COUNTERMEASURES

Although epidemiological data are lacking, it is evident that both acute and chronic physal injuries occur in children’s and youth sports and that some of these injuries may be associated with growth disturbance. A disturbing finding is the growing number of reports of stress related physal injuries affecting young athletes, including those affecting the lower extremities. Coaches and others associated with children’s and youth sports should be educated about the potential for growth plate injury and recommended strategies for prevention. The following preventive measures may be worthy of consideration.

- Training and skill development should be individualised to reduce risk of acute and stress related physal injury; in particular, coaches should reduce training loads and delay skill progressions for young athletes experiencing periods of rapid growth. Careful measurement of height at three month intervals will provide coaches with data to estimate growth rate. Height measurements should be taken at the same time of day (preferably in the morning) and should not be taken after a workout.
- Coaches should use a variety of drills or activities during practice to avoid excessively repetitive movements that may result in overuse injury. Emphasis should be on quality of workouts rather than training volume.
- Periodic physical examination should be carried out so that stress related growth plate and other overuse injuries can be diagnosed at an early stage and modifications made to the training programme to assist in the recovery process; when indicated, radiographs of symptomatic physal areas should be administered to rule out stress changes.
- Although data on injury prevention are lacking, physical conditioning, including strengthening, range of motion, and proprioceptive exercises, may help to reduce both acute and chronic physal injury.
- Trained personnel such as certified athletic trainers should supervise injury rehabilitation and return to practice.
- Periodisation of training may also help to reduce stress related physal injuries and prevent overtraining. This technique involves the systematic cycling of training loads over set periods of time with well defined rest periods.

### What is already known on this topic

- Both acute and chronic physeal injuries occur in paediatric sports; most resolve with treatment and rest, but some—particularly acute injuries—may result in growth disturbance
- American football is the sport most often connected with physeal fractures, but most other sports are also represented

### What this study adds

- There is documentation of sport related physeal acute injuries affecting young athletes involved in a wide range of sports activities
- There is documentation of sport related physeal stress injuries affecting young athletes involved in overhead, running-related, and upper extremity weight bearing sports
- There is concern for the potential of growth disturbance and deformity secondary to sport related acute and chronic physeal injury

- When acute epiphyseal fracture involves a joint, it is recommended that the child not participate in contact sports for at least four to six months to prevent reinjury.<sup>4</sup> Long term follow up is usually necessary to monitor the child's recuperation and growth. Evaluation includes x ray examination of matching limbs at three to six month intervals for at least two years.<sup>153</sup>
- For collision sports, such factors as maturity, fitness levels, and achievement and skill in the sport should be considered as possible criteria for equalising competition among chronological age peers and preventing unnecessary acute physeal and other injuries.<sup>154–156</sup> A non-invasive measure for grouping young athletes has been proposed.<sup>157</sup>

Finally, the channels of communication between the coach and the athlete's doctor must be kept open so that young athletes can be assessed at the earliest opportunity should they develop symptoms. Severe pain around a joint, whether of sudden or gradual onset, may be the symptom of significant growth plate changes, which require examination by a doctor, prompt treatment, and specific recommendations about return to activity. A child should never be allowed or expected to "work through the pain."

### CHALLENGES FOR FUTURE RESEARCH

This scientific review of the literature underscores the need for prospective cohort studies to clarify the distribution and determinants of physeal injuries affecting young athletes. Important to this research is the meticulous documentation of growth plate injuries on injury report forms that include appropriate designations for both physeal and apophyseal injuries.

Prospective cohort studies should include analytical as well as descriptive components, so that possible risk factors and viable preventive measures can also be determined. Studies need to account for the multivariate nature of sports injuries by including as many relevant risk factors as possible.<sup>158</sup> A risk factor of particular interest is whether periods of rapid growth relate to an increased risk of injury and, accordingly, whether training programmes designed to reduce the training loads

during these periods may also result in a reduced risk of injury. Studies that test the effectiveness of pre-participation musculoskeletal screening are also recommended.

It is only through concerted collaborative efforts that optimal results can be achieved. The research team should include the coach, athletic trainer, doctor, and epidemiologist, who interact in a very dynamic manner. In addition, it is important to emphasise that every effort should be made by the research team to establish an open and trusting dialogue with young athletes and their parents. It is only after this is achieved that an adequate database can be established.

### Authors' affiliations

**D Caine**, Department of Physical Education, Health and Recreation, Western Washington University, Bellingham, WA, USA

**J DiFiori**, Division of Sports Medicine, Department of Family Medicine, University of California, Los Angeles, CA, USA

**N Maffulli**, Department of Trauma and Orthopedic Surgery, Keele University School of Medicine, Stoke on Trent ST4 7QB, UK

Competing interests: none declared

### REFERENCES

- 1 **Caine D**. Growth plate injury and bone growth: an update. *Pediatr Exerc Sci* 1990;**2**:209–29.
- 2 **Caine D**. Injury and growth. In: Sands WA, Caine D, Borms J, eds. *Scientific aspects of women's gymnastics*. Basel: Karger, 2003;**45**:46–71.
- 3 **Garland JJ**. *Fundamentals of orthopedics*, 5th ed. Philadelphia: Saunders, 1987.
- 4 **Ogden JA**. *Skeletal injury in the child*. New York: Springer-Verlag, 2000.
- 5 **Flachsmann R**, Broom ND, Hardy AE, et al. Why is the adolescent joint particularly susceptible to osteochondral shear fracture? *Clin Orthop Rel Res* 2000;**381**:212–21.
- 6 **Micheli LJ**. Pediatric and adolescent sports injury: recent trends. In: Pandolf KB, eds. *Exercise and sport science reviews*. New York: Macmillan, 1986:359–74.
- 7 **Larson RL**, McMahon RO. The epiphyses and the childhood athlete. *JAMA* 1966;**7**:607–12.
- 8 **Bright RW**, Burstein AH, Elmore SM. Epiphyseal-plate cartilage: a biomechanical and histological analysis of failure modes. *J Bone Joint Surg [Am]* 1974;**56**:688–703.
- 9 **Alexander CJ**. Effect of growth rate on the strength of the growth plate-shaft function. *Skeletal Radiol* 1976;**1**:67–76.
- 10 **Morscher E**. Strength and morphology of growth cartilage under hormonal influence of puberty. *Reconstr Surg Traumatol* 1968;**10**:1–96.
- 11 **Speer DP**, Braun JK. The biomechanical basis of growth plate injuries. *Phys Sportsmed* 1985;**13**:72–8.
- 12 **Aldridge MJ**. Overuse injuries of the distal radial growth epiphysis. In: Hoshizaki BT, Salmela JH, Petiot B, eds. *Diagnostics, treatment and analysis of gymnastic talent*. Montreal: Sports Psyche Editions, 1987:25–30.
- 13 **Bailey DA**, Wedge JH, McCulloch RG, et al. Epidemiology of fractures of the distal end of the radius in children as associated with growth. *J Bone Joint Surg [Am]* 1989;**71**:1225–31.
- 14 **Peterson HA**, Madhok R, Benson JT, et al. Physeal fractures. Part I. Epidemiology in Olmsted County, Minnesota, 1979–1988. *Pediatr Orthop* 1994;**14**:423–30.
- 15 **Peterson CA**, Peterson HA. Analysis of the incidence of injuries to the epiphyseal growth plate. *J Trauma* 1972;**12**:275–81.
- 16 **Benton JW**. Epiphyseal fracture in sports. *Phys Sportsmed* 1982;**10**:63–71.
- 17 **DiFiori JP**, Puffer JC, Aish B, et al. Wrist pain, distal radial physeal injury and ulnar variance in young gymnasts: does a relationship exist? *Am J Sports Med* 2002;**30**:879–85.
- 18 **Micheli LJ**. Overuse injuries in children's sports: the growth factor. *Orthop Clin Am* 1983;**14**:337–60.
- 19 **Feldman D**, Shrier I, Rossignol M, et al. Adolescent growth is not associated with changes in flexibility. *Clin J Sport Med* 1999;**9**:24–9.
- 20 **Connolly SA**, Connolly LP, Jaramillo D. Imaging of sports injuries in children and adolescents. *Radiol Clin North Am* 2001;**39**:773–90.
- 21 **Salter RB**, Harris WR. Injuries involving the epiphyseal plate. *J Bone Joint Surg [Am]* 1963;**45**:587–622.
- 22 **Barmada A**, Gaynor T, Mubarak SJ. Premature closure following distal tibia physeal fractures. *J Pediatr Orthop* 2003;**23**:733–9.
- 23 **Pappas AM**. Epiphyseal injuries in sports. *Phys Sportsmed* 1983;**11**:140–8.
- 24 **Burkhart SS**, Peterson HA. Fractures of the proximal tibial epiphysis. *J Bone Joint Surg [Am]* 1979;**61**:996–1002.
- 25 **Goldberg VM**, Aadalen R. Distal tibial epiphyseal injuries: the role of athletics in 53 cases. *Am J Sports Med* 1978;**6**:263–8.
- 26 **Oh WH**. Type II epiphyseal fractures may also be responsible for bone growth distortions. *Orthop Rev* 1977;**7**:95–8.
- 27 **Lombardo SJ**, Harvey JP. Fractures of the distal femoral epiphyses. Factors influencing prognosis: a review of thirty-four cases. *J Bone Joint Surg [Am]* 1977;**59**:742–51.

- 28 **Stephens DC**, Louis E, Louis DS. Traumatic separation of the distal femoral epiphyseal cartilage plate. *J Bone Joint Surg [Am]* 1974;**56**:1383-90.
- 29 **Moën CT**, Pelker RR. Biomechanical and histological correlations in growth plate failure. *J Pediatr Orthop* 1984;**4**:180-4.
- 30 **Chung SM**, Batterman SC, Brighton CT. Shear strength of the human femoral capital epiphyseal plate. *J Bone Joint Surg [Am]* 1976;**58**:94-103.
- 31 **Ogden JA**. Injury to the growth mechanisms of the immature skeleton. *Skeletal Radiol* 1981;**6**:237-53.
- 32 **Fischer MD**, McElfresh EC. Physseal and periphyseal injuries of the hand. *Hand Clin* 1994;**10**:287-301.
- 33 **Krueke-Franke M**, Siebert CH, Pfoerringer W. Sports-related epiphyseal injuries of the lower extremity. *J Sports Med Phys Fitness* 1992;**32**:106-11.
- 34 **Rogers LF**, Jones S, Davis AR, et al. "Clipping injury" fracture of the epiphysis in the adolescent football player: an occult lesion of the knee. *Am J Roentgenol Radium Ther Nucl Med* 1974;**121**:69-78.
- 35 **Rovere GD**, Gristina AG, Stolzer WA. Stalking the vulnerable epiphysis. *Phys Sportsmed* 1975;**3**:51-2.
- 36 **Ryan JR**, Saliciccoli DG. Fracture of the distal radial epiphysis in adolescent weight lifters. *Am J Sports Med* 1976;**9**:26-7.
- 37 **Simpson WC**, Fardon DF. Obscure distal femoral epiphyseal injury. *South Med J* 1976;**69**:1338-40.
- 38 **Gumbs VI**, Segal D, Halligan JB, et al. Bilateral distal radius and ulnar fracture in adolescent weight lifters. *Am J Sports Med* 1982;**10**:375-9.
- 39 **Collins WJ**, Hofner RG. A lower leg epiphyseal plate injury in a young athlete. Is it just an ankle sprain? *Athletic Training* 1984;**19**:61-4.
- 40 **Lemire L**, Rosman M. Sternoclavicular epiphyseal separation with adjacent clavicular fracture. *J Pediatr Orthop* 1984;**4**:118-20.
- 41 **Hernandez J**, Peterson HA. Fracture of the distal radial physis complicated by compartment syndrome and premature physseal arrest. *J Pediatr Orthop* 1986;**6**:627-30.
- 42 **Abrams J**, Bennett E, Kumar SJ, et al. Salter-Harris Type III fracture of the proximal fibula. *Am J Sport Med* 1993;**14**:514-16.
- 43 **Jenkins NH**, Mintow-Czyz WJ. Bilateral fracture-separations of the distal radial epiphyses during weight-lifting. *Br J Sports Med* 1986;**20**:72-3.
- 44 **Weiss APC**, Sponseller PD. Salter-Harris Type I fracture of the distal radius due to weightlifting. *Orthop Rev* 1989;**18**:233-5.
- 45 **Spinella AJ**, Turco VH. Avulsion fracture of the distal tibial epiphysis in skeletally immature athletes (Juvenile Tillaux Fracture). *Orthop Rev* 1988;**17**:1245-9.
- 46 **Thomas JL**. Epiphyseal plate sparing fixation for Salter Harris IV ankle fractures. *J Foot Surg* 1989;**28**:120-3.
- 47 **Keret D**, Mendez AA, Karcke HT. Type V physseal injury: a case report. *J Pediatr Orthop* 1990;**10**:545-8.
- 48 **Bak K**. Separation of the proximal tibial epiphysis in a gymnast. *Acta Orthop Scand* 1991;**62**:293-4.
- 49 **Meyers MC**, Calvo D, Sterling JC, et al. Delayed treatment of a malreduced distal femoral epiphyseal plate fracture. *Med Sci Sports Exerc* 1992;**24**:1311-15.
- 50 **Hartley JE**, Ricketts DM. An unusual proximal tibial epiphyseal injury. *International Journal of the Care of the Injured* 1993;**24**:568-9.
- 51 **Toto BJ**. Salter-Harris Type I fracture of the closed growth plate of the distal fibular in a high school baseball player. *Chiropractic Sports Medicine* 1993;**7**:90-2.
- 52 **Banks RH**, Lester DK, Shaw BA. Flexion-type Salter II fracture of the proximal tibia. *Clin Orthop Rel Res* 1994;**301**:256-9.
- 53 **Decoster LC**, Vailas JC. Fracture through the distal femoral epiphysis. *J Athl Train* 1995;**30**:154-7.
- 54 **Valverde JA**, Albifiana J, Certucha JA. Early posttraumatic physseal arrest in distal radius after a compression injury. *J Pediatr Orthop* 1996;**5**:57-60.
- 55 **Goldberg BA**, Mansfield DS, Davino NA. Nonunion of a distal femoral epiphyseal fracture-separation. *Am J Orthop* 1996;**25**:773-7.
- 56 **Beck A**, Kundel K, Ruter A. Significance of corrective growth of opposite physses in the surgical correction of deformity following epiphyseal injury around the knee joint. *Knee Surg Sports Traumatol Arthrosc* 1997;**5**:38-41.
- 57 **Brone LA**, Wroble RR. Salter-Harris Type III fracture of the medial femoral condyle associated with an anterior cruciate ligament tear. *Am J Sports Med* 1998;**26**:581-6.
- 58 **Veenema KR**. Valgus knee instability in an adolescent; ligament sprain or physseal fracture? *Phys Sportsmed* 1999;**27**:62.
- 59 **Mudgal CS**, Popovitz LE, Kassir JR. Flexion-type Salter Harris I injury of the proximal tibial epiphysis. *J Orthop Trauma* 2000;**14**:302-5.
- 60 **Shinro T**, Yoshino N, Kubo N, et al. Bilateral epiphyseal fractures of the proximal tibia within a six-month interval: a case report. *J Orthop Trauma* 2000;**14**:585-8.
- 61 **Maffulli N**. Epiphyseal injuries of the proximal phalanx of the hallux. *Clin J Sport Med* 2001;**11**:121-3.
- 62 **Ozer H**, Turanlı S, Baltacı G, et al. Avulsion of the tibial tuberosity with a lateral plateau rim fracture: case report. *Knee Surg Sports Traumatol Arthrosc* 2002;**10**:310-12.
- 63 **Whan A**, Breidahl W, Janes G. MRI of trapped periosteum in a proximal tibial physseal injury of a pediatric patient. *AJR Am J Roentgenol* 2003;**181**:1397-9.
- 64 **Ergun M**, Taskiran E, Ozgurbuz C. Simultaneous bilateral tibial tubercle avulsion fracture in a basketball player. *Knee Surg Sports Traumatol Arthrosc* 2003;**11**:163-6.
- 65 **Goga E**, Gongal P. Severe soccer injuries in amateurs. *Br J Sports Med* 2003;**37**:498-501.
- 66 **Samsoni SR**, Chell J. A complex distal femoral epiphyseal fracture with a Hoffa's fracture. *Injury: International Journal of the Care of the Injured* 2004;**35**:825-7.
- 67 **Larson RL**. Epiphyseal injuries in the adolescent athlete. *Orthop Clin N Am* 1973;**4**:839-54.
- 68 **Stephens DC**, Louis E, Louis DS. Traumatic separation of the distal femoral epiphyseal cartilage plate. *J Bone Joint Surg [Am]* 1974;**56**:1383-90.
- 69 **Criswell AR**, Hand WL, Butler JE. Abduction injuries of the distal femoral epiphysis. *Clin Orthop Rel Res* 1976;**115**:189-94.
- 70 **McNanama GB**, Michelli LJ. The incidence of sport-related epiphyseal injuries in adolescents. *Med Sci Sports* 1977;**9**:57.
- 71 **Cass JR**, Peterson HA. Salter-Harris Type-IV injuries of the distal tibial epiphyseal growth plate, with emphasis on those involving the medial malleolus. *J Bone Joint Surg [Am]* 1983;**65**:1059-70.
- 72 **LaLonde KA**, Letts M. Traumatic growth arrest of the distal tibia: a clinical and radiographic review. *Can J Surg* 2005;**48**:143-7.
- 73 **Rhemrev SJ**, Sleebloom C, Ekelkamp S. Epiphyseal fractures of the proximal tibia. *Injury* 2000;**31**:131-4.
- 74 **Nenopoulos SP**, Papavasiliou VA, Papavasiliou AV. Rotational injuries of the distal tibial growth plate. *J Orthop Sci* 2003;**8**:784-8.
- 75 **Caine DJ**, Maffulli N, eds. *Epidemiology of pediatric sports injuries. Individual sports*. Basel: Karger, 2005.
- 76 **Maffulli N**, Caine DJ, eds. *Epidemiology of pediatric sports injuries. Team sports*. Basel: Karger, 2005.
- 77 **Roser LA**, Clawson DK. Football injuries in the very young athlete. *Clin Orthop Rel Res* 1970;**69**:219-23.
- 78 **Chambers RB**. Orthopedic injuries in athletes (ages 6 to 17). *Am J Sports Med* 1979;**7**:195-7.
- 79 **Zaricnyj B**, Shattuck LJM, Mast TA, et al. Sports-related injuries in school-aged children. *Am J Sports Med* 1980;**8**:318-23.
- 80 **Goldberg B**, Rosenthal PP, Nicholas JA. Injuries in youth football. *Phys Sportsmed* 1984;**12**:122-30.
- 81 **Tursz A**, Crost M. Sport-related injuries in children. A study of their characteristics, frequency, and severity, with comparisons to other types of accidental injuries. *Am J Sports Med* 1986;**14**:294-9.
- 82 **Goldberg B**, Rosenthal PP, Robertson LS, et al. Injuries in youth football. *Pediatrics* 1988;**81**:255-61.
- 83 **Caine D**, Cochrane B, Caine C, et al. An epidemiological investigation of injuries affecting young competitive female gymnasts. *Am J Sports Med* 1989;**17**:811-20.
- 84 **Risser WL**, Risser JNH, Preston D. Weight-training injuries in adolescents. *Am J Dis Child* 1990;**144**:1015-17.
- 85 **Andreasen I**, Fauno P, Lemche P, et al. Soccer injuries among youth. *Scand J Med Sci Sports* 1993;**3**:62-6.
- 86 **Linder MM**, Townsend DJ, Jones JC. Incidence of adolescent injuries in junior high school football and its relationship to sexual maturity. *Clin J Sport Med* 1995;**5**:167-70.
- 87 **Kolt G**, Kirkby RJ. Epidemiology of injury in elite and subelite female gymnasts: a comparison of retrospective and prospective findings. *Br J Sports Med* 1999;**33**:312-18.
- 88 **Kolt G**, Kirkby RJ. *Sports Medicine, Training and Rehabilitation* 1995;**6**:223-31.
- 89 **Stuart MJ**, Morrey MA, Smith AM, et al. Injuries in youth football: a prospective observational cohort analysis among players aged 9 to 13 years. *Mayo Clin Proc* 2002;**77**:317-22.
- 90 **Jaramillo D**, Laor T, Zaleske DJ. Indirect trauma to the growth plate: results of MR imaging after epiphyseal and metaphyseal injury in rabbits. *Radiology* 1993;**187**:171-8.
- 91 **DiFiori JP**, Mandelbaum BR. Wrist pain in a young gymnast: unusual radiographic findings and MRI evidence of growth plate injury. *Med Sci Sports Exerc* 1996;**28**:1453-8.
- 92 **Shih C**, Chang CY, Penn IW. Chronically stressed wrists in adolescent gymnasts: MR imaging appearance. *Radiol* 1995;**195**:855-9.
- 93 **Dotter WE**. Little league's shoulder. *Guthrie Clin Bull* 1953;**23**:68.
- 94 **Adams JE**. Little league shoulder: osteochondrosis of the proximal humeral epiphysis in boy baseball pitchers. *Calif Med* 1966;**105**:22-5.
- 95 **Torg JS**. The little league pitcher. *Am Fam Physician* 1972;**6**:71-6.
- 96 **Calhll BR**, Tullos HS, Fain RH. Little league shoulder: rotational stress fracture of proximal epiphysis. *J Sports Med* 1974;**2**:150-2.
- 97 **Tullos HS**, Fain RH. Little league shoulder: rotational stress fracture of proximal epiphysis. *J Sports Med* 1974;**2**:152-3.
- 98 **Lipscomb AB**. Baseball pitching injuries in growing athletes. *J Sports Med* 1975;**3**:25-34.
- 99 **Hansen NB**. Epiphyseal changes in the proximal humerus of an adolescent baseball pitcher. *Am J Sports Med* 1982;**10**:380-4.
- 100 **Barnett LS**. Little league shoulder syndrome. Proximal humeral epiphysiolysis in adolescent baseball pitchers: a case report. *J Bone Joint Surg [Am]* 1985;**67**:495-6.
- 101 **Albert MJ**, Drvaric DM. Little league shoulder: Case report. *Orthopedics* 1990;**13**:779-81.
- 102 **Carson WG**, Gasser SI. Little league's shoulder. A report of 23 cases. *Am J Sports Med* 1998;**26**:575-80.
- 103 **Ricci AR**, Mason DE. Little league shoulder: case report and literature review. *Del Med J* 2004;**76**:11-14.
- 104 **Flemming JL**, Hollingsworth CL, Squire DL, et al. Little league's shoulder. *Skeletal Radiol* 2004;**33**:352-4.
- 105 **Drescher WR**, Falliner A, Zantop T, et al. Little league shoulder syndrome in an adolescent cricket player. *Br J Sports Med* 2004;**38**:E14.
- 106 **Daldorf PG**, Bryan WJ. Displaced Salter-Harris Type I injury in a gymnast. A slipped capital humeral epiphysis? *Orthop Rev* 1994;**23**:538-41.
- 107 **Boyd KT**, Batt ME. Stress fracture of the proximal humeral epiphysis in an elite junior badminton player. *Br J Sports Med* 1997;**31**:252-3.
- 108 **Johnson JN**, Houchin G. Adolescent athlete's shoulder. A case series of proximal humeral epiphysiolysis in nonthrowing athletes. *Clin J Sport Med* 2006;**16**:84-6.

- 109 **Podestral L**, Sherman MF, Bonamo JR. Distal humeral epiphyseal separation in a young athlete. A case report. *Arch Phys Med Rehabil* 1993;**74**:1216-18.
- 110 **Adams JE**. Injury to the throwing arm: a study of traumatic changes in the elbow joints of boy baseball players. *Calif Med* 1965;**102**:127-32.
- 111 **Hochholzer T**, Schoffl VR. Epiphyseal fractures of the finger middle joints in young climbers. *Wilderness Environ Med* 2005;**16**:139-42.
- 112 **Cahill BR**. Stress fracture of the proximal tibial epiphysis: a case report. *Am J Sports Med* 1977;**5**:186-7.
- 113 **Percy EC**, Gamble FO. An epiphyseal stress fracture of the foot and shin splints in an anomalous calf muscle in a runner. *Brit J Sports Med* 1980;**14**:110-13.
- 114 **Godshall RW**, Hansen CA, Rising DC. Stress fractures through the distal femoral epiphysis in athletes. A previously unreported entity. *Am J Sports Med* 1981;**9**:114-16.
- 115 **Weber PC**. Salter-Harris Type II stress fracture in a young athlete. *Orthop* 1988;**11**:309-11.
- 116 **Liebling MS**, Berdon WE, Ruzal-Shapiro C, et al. Gymnast's wrist (pseudorickets growth plate abnormality) in adolescent athletes: findings on plain films and MR imaging. *AJR Am J Roentgenol* 1995;**164**:157-9.
- 117 **Wall EJ**. Knee injury: gymnastics. *Med Sci Sports Exerc* 1997;**29**(suppl):S152.
- 118 **Wall EJ**. Growth plate overuse syndrome of the ankle in athletes. *Med Sci Sports Exerc* 1997;**29**(suppl):S299.
- 119 **Sato T**, Shinozaki T, Fukudo T, et al. Atypical growth plate closure: a possible chronic Salter and Harris Type V injury. *J Pediatr Orthop* 2002;**11**:155-8.
- 120 **Nanni M**, Butt S, Mansour R. Stress-induced Salter-Harris I growth plate injury of the proximal tibia: first report. *Skeletal Radiol* 2005;**34**:405-10.
- 121 **Laor T**, Wall EJ, Vu LP. Physseal widening in the knee due to stress injury in child athletes. *AJR Am J Roentgenol*, 2006;186, 1260-4.
- 122 **Read MT**. Stress fractures of the distal radius in adolescent gymnasts. *Br J Sports Med* 1981;**15**:272-6.
- 123 **Roy S**, Caine D, Singer K. Stress changes of the distal radial epiphysis in young gymnasts. A report of twenty-one cases and a review of the literature. *Am J Sports Med* 1985;**13**:301-8.
- 124 **Fliegel CP**. Stress related widening of the radial growth plate in adolescents. *Ann Radiol* 1986;**29**:374-6.
- 125 **Vender MI**, Watson K. Acquired Madelung-like deformity in a gymnast. *J Hand Surg [Am]* 1988;**13**:19-21.
- 126 **Carter SR**, Aldridge MJ. Stress injury of the distal radial growth plate. *J Bone Joint Surg [Br]* 1988;**70**:834-6.
- 127 **Yong-Hing K**, Wedge JN, Bowen CV. Chronic injury to the distal ulnar and radial growth plates in an adolescent gymnast. *J Bone Joint Surg [Am]* 1988;**70**:1087-9.
- 128 **Albanese SA**, Palmer AK, Kerr DR, et al. Wrist pain and distal growth plate closure of the radius in gymnasts. *J Pediatr Orthop* 1989;**9**:23-8.
- 129 **Ruggles DL**, Peterson HA, Scott SG. Radial growth plate injury in a female gymnast. *Med Sci Sports Exerc* 1991;**23**:393-6.
- 130 **Li DK**, Lloyd-Smith R. Wrist pain in an adolescent gymnast. *Clin J Sport Med* 1991;**1**:259-61.
- 131 **Frizzell JB**, Brunet G. Stress changes of the distal radial physis. *Can Assoc Radiol J* 1977;**48**:54-5.
- 132 **Carek PJ**, Fumich RM. Stress fracture of the distal radius. Not just a risk for elite gymnasts. *Phys Sportsmed* 1992;**20**:115-18.
- 133 **Nattiv A**, Mandelbaum BR. Injuries and special concerns in female gymnasts. Detecting, treating, and preventing common problems. *Phys Sportsmed* 1993;**21**:66-82.
- 134 **Howe W**, Caine D, Keeler L, et al. Wrist pain: gymnastics. *Med Sci Sports Exerc* 1997;**29**(suppl):S151.
- 135 **Bak K**, Boeckstyns M. Epiphysiodesis for bilateral irregular closure of the distal radial physis in a gymnast. *Scand J Med Sci Sports* 1997;**7**:363-6.
- 136 **Brooks TJ**. Madelung deformity in a collegiate gymnast: a case report. *J Athl Train* 2001;**36**:170-3.
- 137 **Caine D**, Knutzen K, Howe W, et al. A three-year epidemiological study of injuries affecting young female gymnasts. *Physical Therapy in Sport* 2003;**4**:10-23.
- 138 **Attkiss KJ**, Buncke JH. Physseal growth arrest of the distal phalanx of the thumb in an adolescent pianist: a case report. *J Hand Surg [Am]* 1998;**23**:532-5.
- 139 **Gelbke H**. Tierexperimentelle. Unterbuchungen zur Frage des enthandralen Knochenwachstums unter Zug. *Langenbecks Arch Klin Chir Ver Dtsch Z Chir* 1950;**266**:271-84.
- 140 **Lamb DR**, Van Huss WD, Carrow RD, et al. Effects of prepubertal physical training on growth, voluntary exercise, cholesterol and basal metabolism in rats. *Research Quarterly of the American Association for Health, Physical Education and Recreation*. 1969;**40**:123-33.
- 141 **Tipton CM**, Matthes RD, Maynard JA. Influence of chonic exercise on rat bones. *Med Sci Sports Exerc* 1972;**4**:55.
- 142 **Kiiskinen A**. Physical training and connective tissues in young mice: physical properties of Achilles tendons and long bones. *Growth* 1977;**41**:123-37.
- 143 **Simon MR**. The effects of dynamic loading on the growth of epiphyseal cartilage in the rat. *Acta Anat* 1978;**102**:176-83.
- 144 **Matsuda JJ**, Zernicke RF, Vailas AC, et al. Structural and mechanical adaptation of immature bone to strenuous exercise. *J Appl Physiol* 1986;**60**:2028-34.
- 145 **LeVeau BF**, Bernhardt DB. Developmental biomechanics. Effects of forces on the growth, development and maintenance of the human body. *Phys Ther* 1984;**64**:1-5.
- 146 **Auberge T**, Zenny JC, Duvallet A, et al. Study of bone maturation and osteo-articular lesions in top level sportsmen: a review of 105 cases. *J Radiol (Paris)* 1984;**65**:555-61.
- 147 **Szot Z**, Boron Z, Galaj Z. Overloading changes in the motor system occurring in elite gymnasts. *Int J Sports Med* 1985;**6**:36-40.
- 148 **Caine D**, Roy S, Singer K, et al. Stress changes of the distal radial growth plate. A radiographic survey of 60 young competitive gymnasts and an epidemiologic review of the related literature. *Am J Sports Med* 1992;**20**:290-8.
- 149 **DeSmet L**, Claessons A, Lefevre J, et al. Gymnast wrist: an epidemiological survey of the ulnar variance in elite female gymnasts. *Am J Sports Med* 1994;**22**:846-50.
- 150 **Chang CY**, Shih C, Penn IW, et al. Wrist injuries in adolescent gymnasts of a chinese operal school: radiographic survey. *Radiology* 1995;**195**:861-4.
- 151 **DiFiori JP**, Puffer JC, Mandelbaum BR, et al. Distal radial growth plate injury and positive ulnar variance in nonelite gymnasts. *Am J Sports Med* 1997;**25**:763-8.
- 152 **Lishen Q**, Jianhua O. Epiphysseal injury in gymnasts. *Chinese Journal of Sports Medicine* 1983;**2**:7-12.
- 153 **National Institute of Arthritis and Musculoskeletal and Skin Diseases**. National Institutes of Health. Questions and answers about Growth Plate Injuries. NIH Publication No. 02-5028. October, 2001.
- 154 **Hafner JK**, Scott SE, Vera G, et al. Interscholastic athletics. Method for selection and classification of athletes. *N Y State J Med* 1982;**82**:1449-59.
- 155 **Roy MA**, Bernard D, Benoit R, et al. Bodychecking in peewee hockey. *Phys Sportsmed* 1989;**14**:465-71.
- 156 **Caine DJ**, Lindner K. Preventing injury to young athletes. Part 2. Preventive measures. *Journal of the Canadian Association for Health Physical Education and Recreation* 1990;**56**:24-30.
- 157 **Mirwald RL**, Baxter-Jones ADG, Bailey DA, et al. An assessment of maturity from anthropometric measurements. *Med Sci Sports Exerc* 2002;**34**:689-94.
- 158 **Bahr R**, Holme I. Risk factors for sports injuries: a methodological approach. *Br J Sports Med* 2003;**37**:384-92.